

# SPM Maps of Relative Hypometabolism and Relatively Preserved Brain Regions

*Clinical cases*

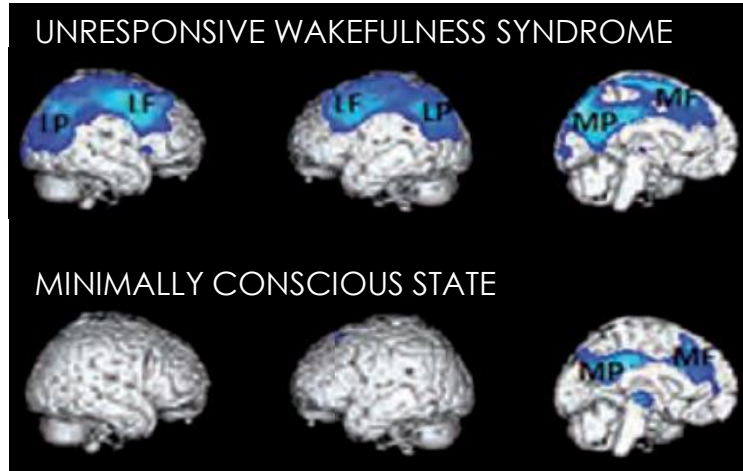
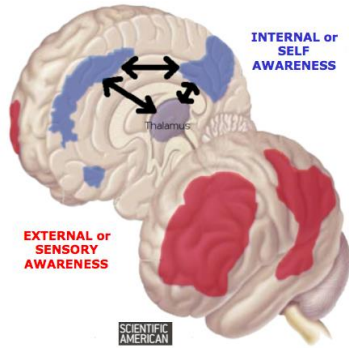
CSG PET workshop

Jitka ANNEN, PhD  
Coma Science Group  
University Hospital & University of Liège  
Dept. of Data Analysis, University of Gent  
Contact: [Jitka.annen@uliege.be](mailto:Jitka.annen@uliege.be)

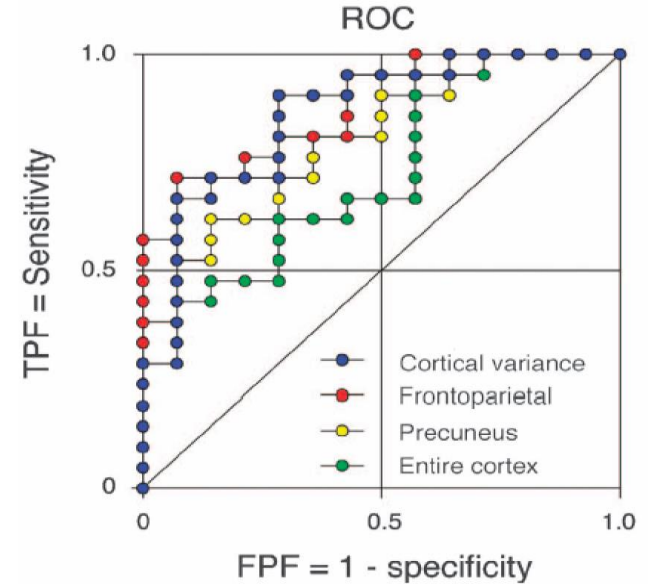


# Regional brain metabolism = informative

## Hypometabolic areas



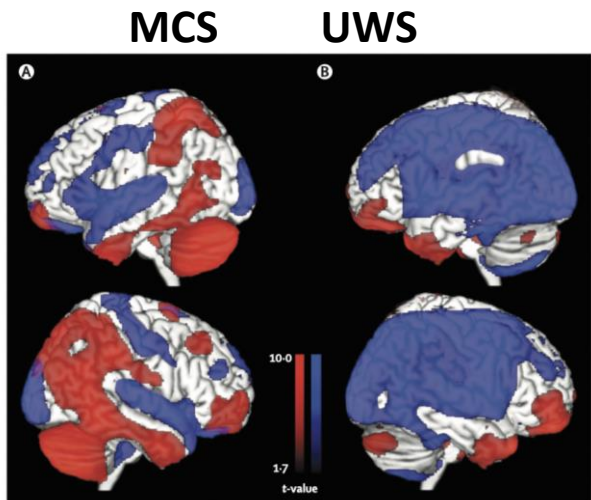
## Cerebral metabolic rate of glucose



Thibaut et al, *J Rehabil Med*, 2012

Stender et al, *J Cereb Blood Flow & Metab*, 2015

# Voxel-wise interpretation of relative preservation and/or hypometabolism



-MCS patients: relative preservation of glucose uptake in the frontoparietal network

-UWS patients: widespread reduction of glucose uptake throughout the cortex

-Diagnosis is based on **visual evaluation by expert** of metabolic patterns

Coma Recovery Scale-Revised results			
	UWS	MCS	Total
<b>Clinical consensus diagnosis</b>			
VS/UWS	33 (37%)	18 (20%)	51 (57%)
MCS	2 (2%)	36 (40%)	38 (43%)
Total	35 (39%)	54 (61%)	89 (100%)
<b><sup>18</sup>F-FDG PET</b>			
VS/UWS	24 (21%)	5 (4%)	29 (26%)
MCS	12 (14%)	71 (63%)	83 (74%)
Total	36 (32%)	76 (68%)	112 (100%)
<b>Mental imagery fMRI</b>			
VS/UWS	25 (36%)	23 (33%)	48 (69%)
MCS	3 (4%)	19 (27%)	22 (31%)
Total	28 (40%)	42 (60%)	70 (100%)

Annotations:

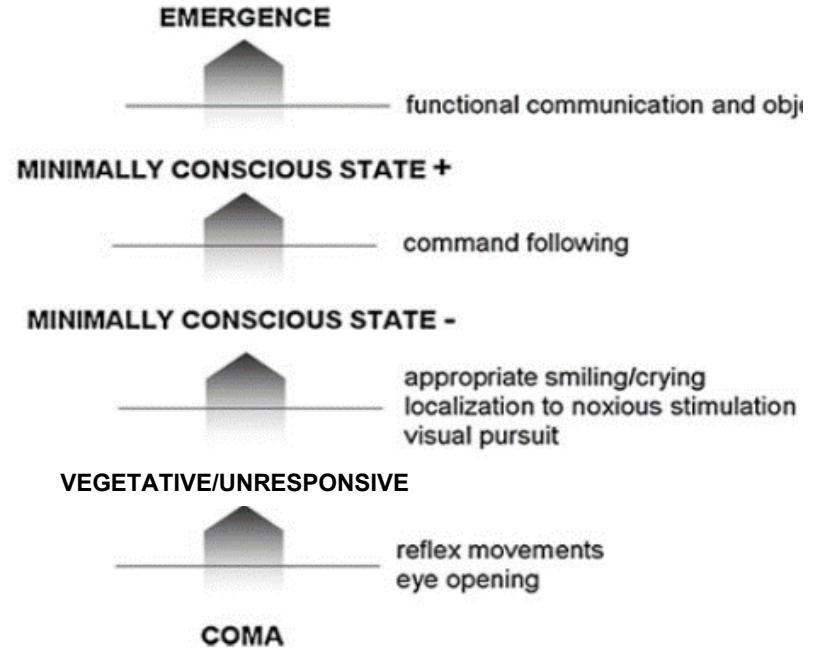
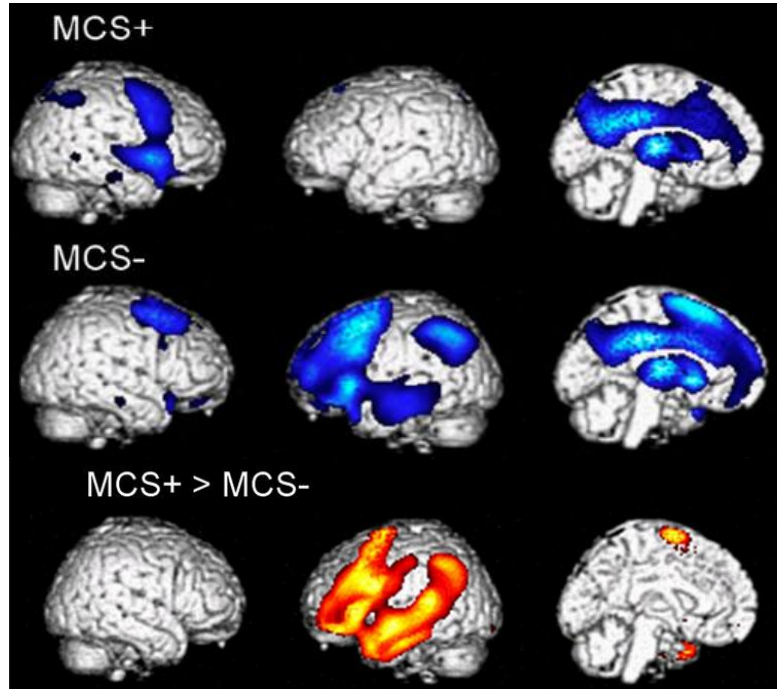
- 35% clinical misdiagnosis (pointing to 18 MCS in Clinical consensus diagnosis)
- 33% CRS-R misdiagnosis (pointing to 12 MCS in <sup>18</sup>F-FDG PET)
- 75% recovered consciousness (pointing to 23 MCS in Mental imagery fMRI)

Stender\*, Gosseries\* et al. 2009

128 patients

(81 MCS, 41 UWS, 4 LIS)

# Brain metabolism patterns underlie different behaviors



Bruno et al, *J Neurology*, 2011

Aubinet et al, *NeuroRehab Neural Repair*, 2020

# You are the expert! Or will become one

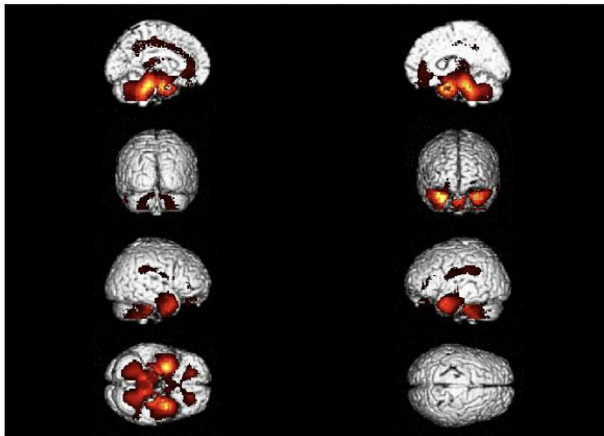
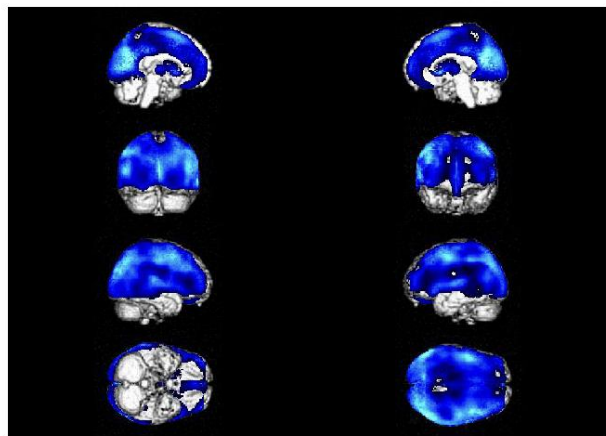
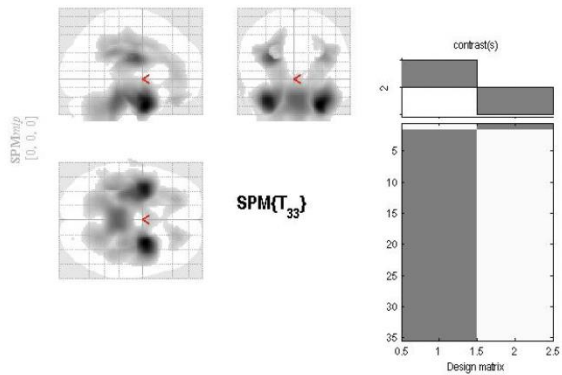
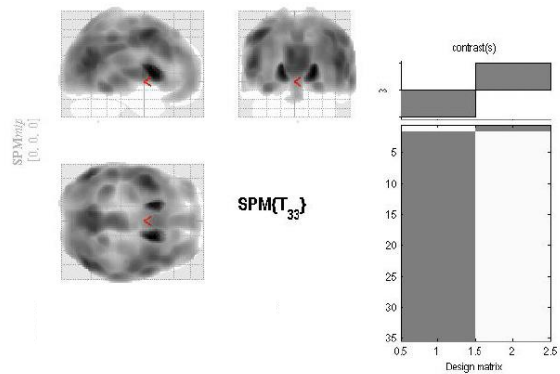


Image A – Healthy control

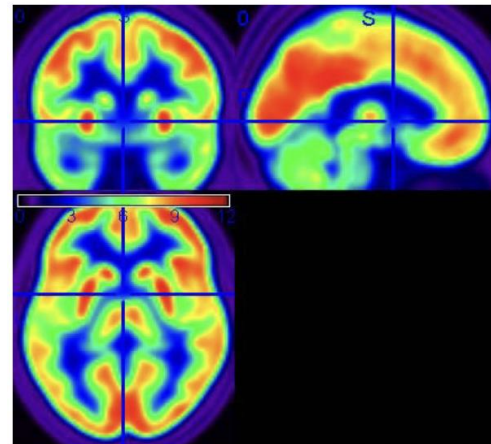
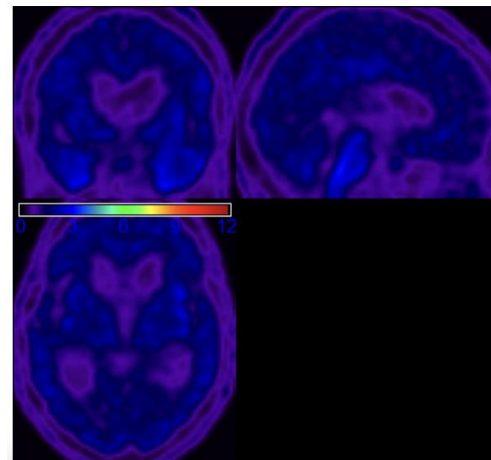
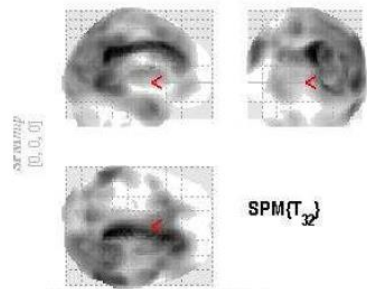


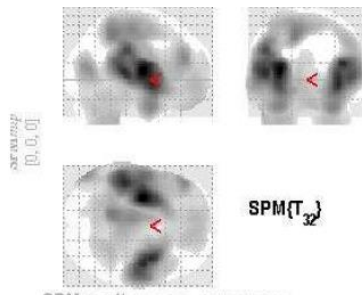
Image B - Patient



# You are the expert! Or will become one



t1 + 1 year



t1 + 1 year

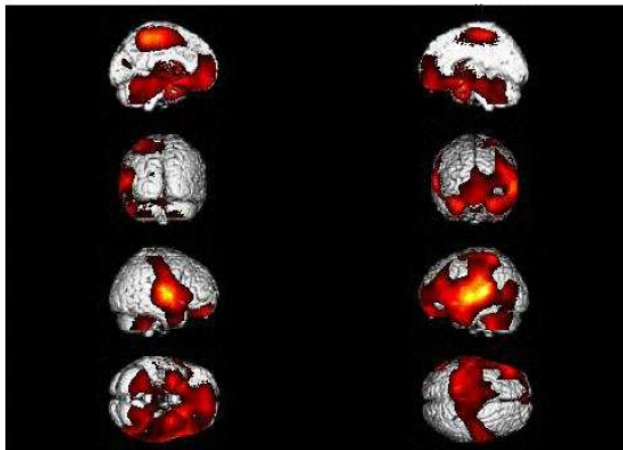
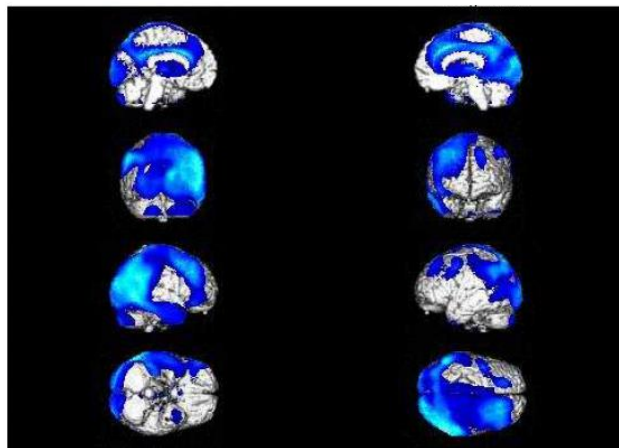


Image A – Healthy control

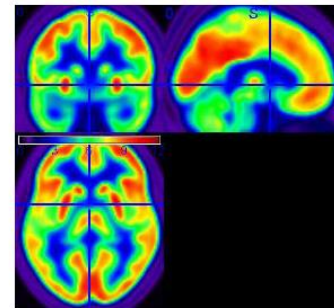


Image B: Patient at t1

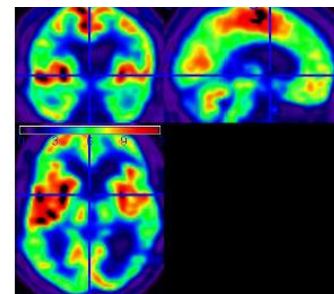
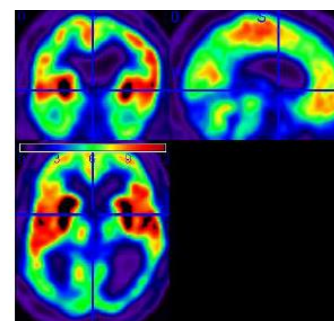
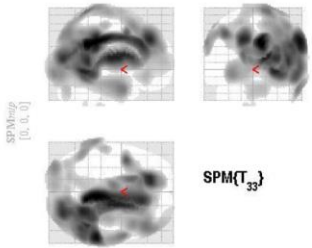


Image C: Patient at t1 + 1 year

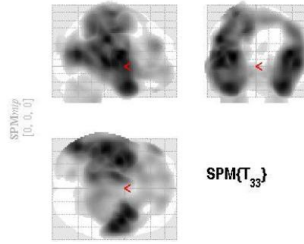




# You are the expert! Or will become one

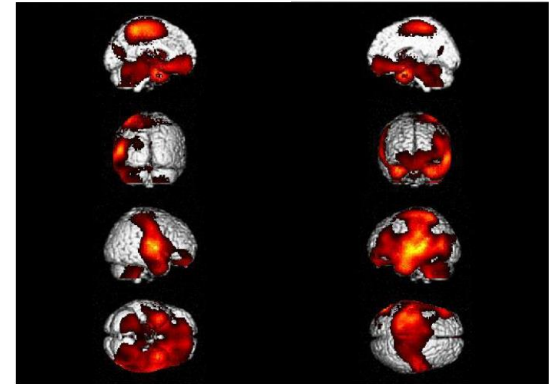
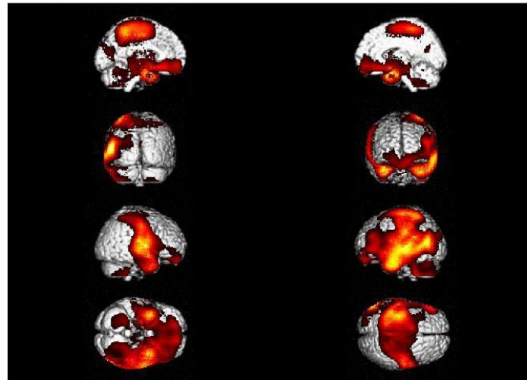
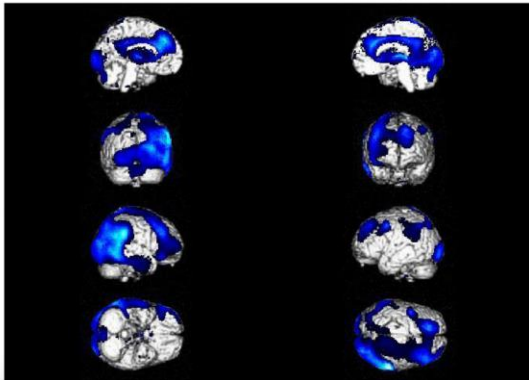
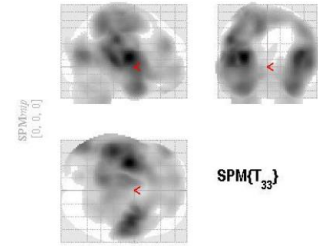


t1+ 5years



t1+ 5years

t1+5years > T1



# You are the expert! Or will become one

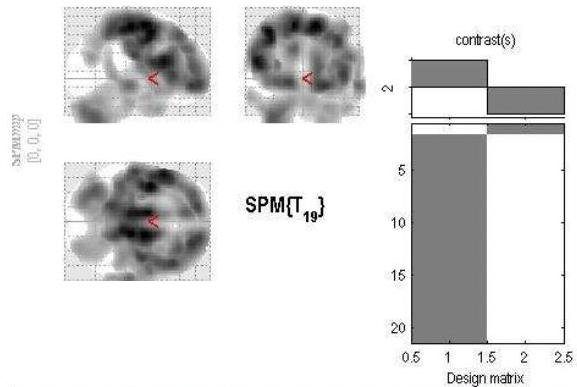
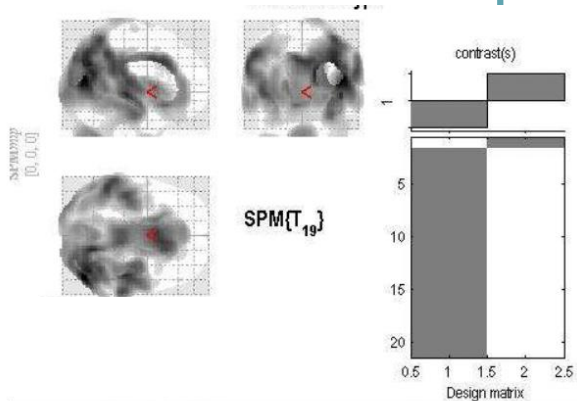


Image A – Healthy control

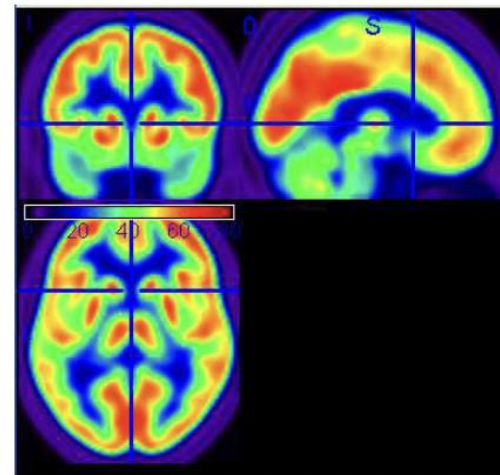
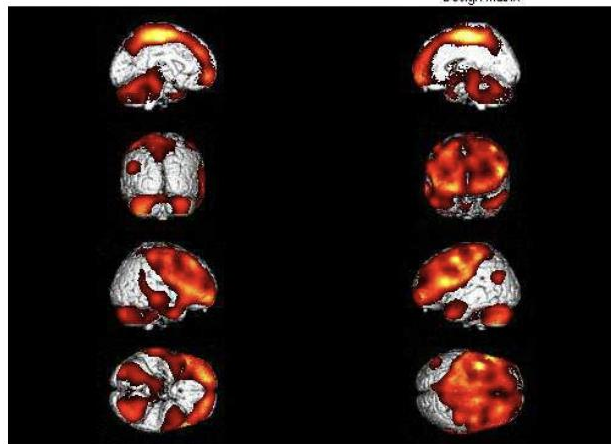
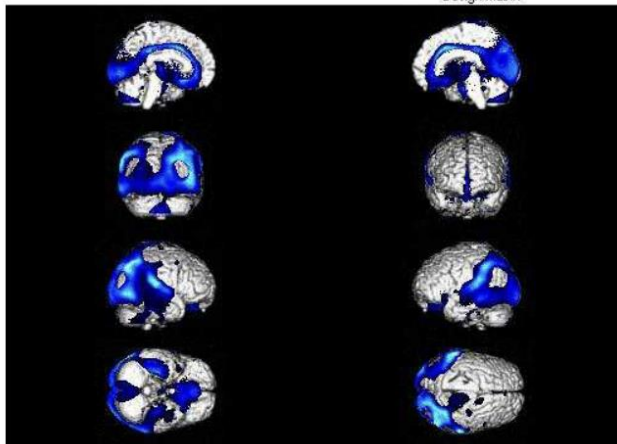
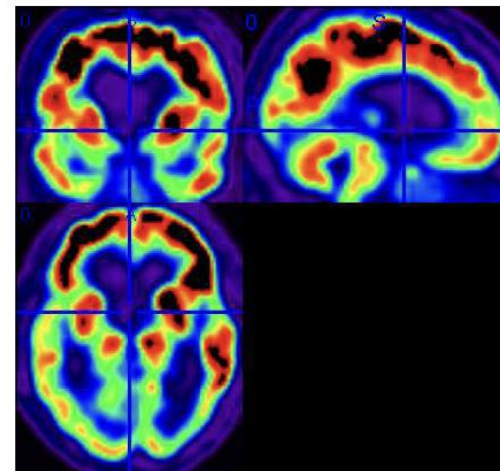
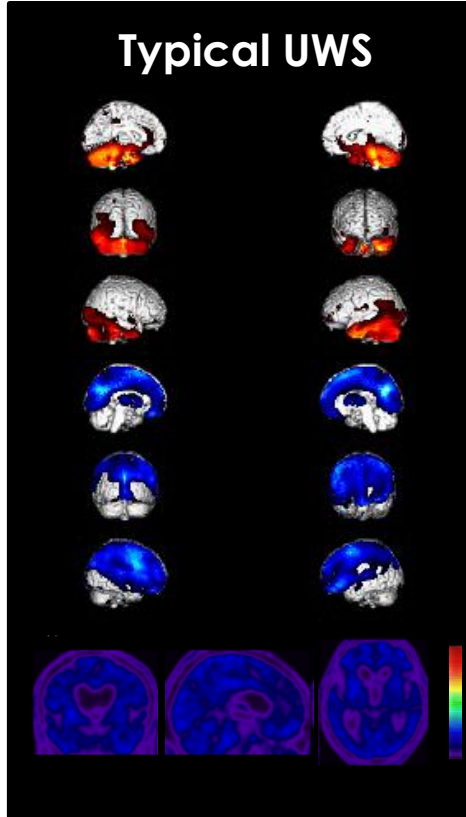


Image B - Patient





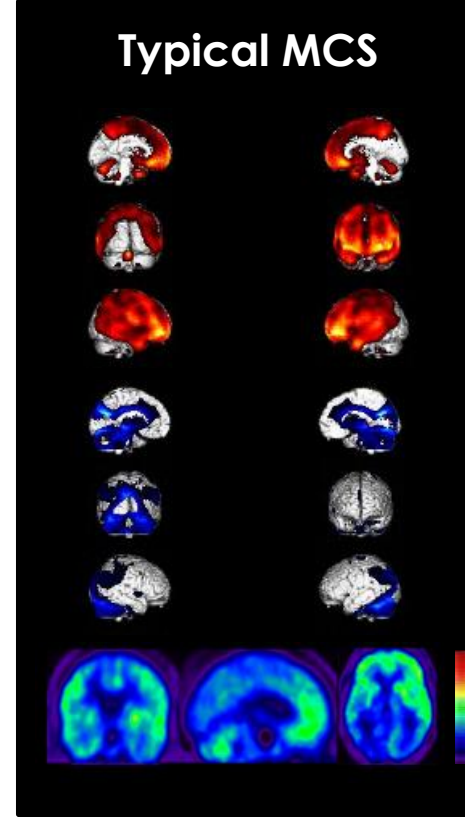
# PET to compliment clinical diagnosis



Preserved  
brain areas

Hypometabolic  
brain regions

SUV



Thank you for your attention.

Questions?

Contact: [Jitka.annen@uliege.be](mailto:Jitka.annen@uliege.be)